Sarhad *et al. BMC Research Notes* (2025) 18:231
https://doi.org/10.1186/s13104-025-07297-x

BMC Research Notes

RESEARCH NOTE Open Access

Effects of non-ionizing radiation on the thyroid gland in rats

Zeynab Seyedi Sarhad[1], Amirali Ebrahimbabaei[2], Alireza Tavassoli[3] and Manzarbanoo Shojaeifard[1,4*]

Abstract

Objectives This study evaluated the effects of non-ionizing electromagnetic radiation on rat thyroid function and histopathology. Forty female and thirty male Sprague-Dawley rats (200–220 g, 2 months old) were exposed to 2.45 GHz Wi-Fi, mobile jammer radiation, or a sham condition. In Group A, male rats were exposed to Wi-Fi or mobile jammers for 2 h daily for two weeks. The devices were located within a one-meter radius of the animal cage, either on or off. In the Sham group, the experimental setup was like the other groups, but the irradiating devices were turned off. Group B included non-pregnant females, pregnant (exposed and control subgroups), and their offspring. Thyroid hormones in the serum were measured, and the histology was microscopically analyzed, focusing on areas of colloid and epithelium in the thyroid follicles.

Results Compared to the control group, T4 hormone levels were significantly different in male rats exposed to mobile jammer radiation (p-value = 0.037). In group B, significant differences were found solely in the male offspring regarding T3 levels due to jammer exposure (average = 109.00 for male offspring in the experiment vs. average = 65.50 for those in the control, p-value < 0.001). Additionally, histopathological findings indicated significant differences as well. These results highlight a potential link between exposure to electromagnetic radiation and changes in thyroid endocrine and histological parameters. Our findings suggest that ongoing assessment of existing safety guidelines on non-ionizing radiation exposure is necessary, especially concerning its effects on thyroid hormone levels and follicular histology.

Keywords Non-ionizing radiation, Thyroid gland physiology, Electromagnetic fields (EMF), Histopathology, Thyroid hormone metabolism

Introduction

Electromagnetic waves are among the most significant environmental pollutants in the world [1]. Approximately three-quarters of the global population relies on telecommunication systems [2]. Radiation is energy transferred from a source through waves or particles and is classified as ionizing or non-ionizing. The energy absorbed generates heat, inducing electrical currents in cells, leading to changes in cell metabolism and membrane permeability [3]. Moreover, non-thermal effects, including oxidative stress and decreased activity of antioxidant enzymes, can lead to tissue disruption [2]. Oxidative stress affects the

*Correspondence:
Manzarbanoo Shojaeifard
shojaeim@sums.ac.ir
[1]Ionizing and Non-Ionizing Radiation Protection Research Center (INIRPRC), School of Paramedical Sciences, Shiraz University Medical Sciences, Shiraz, Iran
[2]Student Research Committee, Fasa University of Medical Sciences, Fasa, Iran
[3]Department of Pathology, School of Medicine, Fasa University of Medical Sciences, Fasa, Iran
[4]Department of Physiology, Fasa University of Medical Sciences, Fasa, Iran

© The Author(s) 2025. **Open Access** This article is licensed under a Creative Commons Attribution-NonCommercial-NoDerivatives 4.0 International License, which permits any non-commercial use, sharing, distribution and reproduction in any medium or format, as long as you give appropriate credit to the original author(s) and the source, provide a link to the Creative Commons licence, and indicate if you modified the licensed material. You do not have permission under this licence to share adapted material derived from this article or parts of it. The images or other third party material in this article are included in the article's Creative Commons licence, unless indicated otherwise in a credit line to the material. If material is not included in the article's Creative Commons licence and your intended use is not permitted by statutory regulation or exceeds the permitted use, you will need to obtain permission directly from the copyright holder. To view a copy of this licence, visit http://creativecommons.org/licenses/by-nc-nd/4.0/.

redox imbalance between reactive oxygen species (ROS) and antioxidant defense [4]. Antioxidants are molecules that can safely interact with free radicals and terminate the chain reaction before vital molecules are damaged. They are essential for protecting cells from damage [5]. The body's antioxidant defense prevents the formation of radicals, scavenges ROS through enzymes, and repairs ROS-induced brain damage [6].

The thyroid gland regulates the basal metabolic rate through the secretion of the hormones triiodothyronine (T3) and thyroxine (T4), which trigger gene expression to increase metabolism and thermogenesis. In particular, it generates high levels of hydrogen peroxide (H2O2), especially in response to thyrotropin [7]. Thyroid peroxidase uses H2O2 as a substrate to enable thyroid hormone synthesis, and it can harm thyroid gland cells [5]. When exposed to non-ionizing radiation, free radicals are typically formed in the thyroid glands. We have focused on ROS generation from the perspective of the oxygen metabolic process, particularly in the thyroid glands. Studies over the last few years have reported altered thyroid activity in rats [8]. The jammer router blocks signal transmission and radiofrequency waves reception between base stations and the receiving device [9]. According to the design parameters, the jammer system transmits noise on the considered frequency band [10]. The jamming distance indicates the jammer's power, which is affected by the jamming-to-signal ratio, and the communication is disturbed by interference from radio waves between 3 kHz and 300 GHz [11]. Wi-Fi networks operating at 2.45 GHz emit electromagnetic fields (EMFs), which may affect organs during prolonged exposure. Pregnant and offspring animals are the most data available regarding jammer radiation data, indicating thyroid stress responses [12]. There are health risks from electromagnetic radiation from mobile phones, towers, and power lines, which are linked to human cancer and animal health effects. This study evaluated the thyroid gland characteristics in rats after two weeks of exposure to controlled Wi-Fi or a mobile jammer.

Table 1 Electromagnetic field (EMF) characteristics of the mobile jammer and Wi-Fi modem, including frequency band, power ratio, power density, and ICNIRP exposure percentage

Sources	Mobile jammer	Wi-Fi modem
Frequency band	1079–1763 MHz	2.45 GHz
Power ratio (dBmW)	-36 ± 3	-81 ± 3
Power density (μw/m^2)	24.79000	00.00215
ICNIRP* (%)	0.22	0.00

*Determining the limits of exposure to non-ionizing radiation, especially in the frequency range of radio and microwave radiation. The International Commission on Non-Ionizing Radiation Protection (ICNIRP) safeguards against non-ionizing radiation by providing scientific guidance on its health and environmental effects. The ICNIRP Guidelines limit exposure to electromagnetic fields, protecting individuals from radiofrequency fields (RF) from 100 kHz to 300 GHz, including 5G, WiFi, Bluetooth, mobile phones, and base stations

Materials and methods

The experiment involved 30 female and 30 male Sprague-Dawley rats, aged 2 months and weighing 200–220 g, obtained from Shiraz University's Comparative Experimental Medicine Center, divided into two major groups. Rats had ad libitum access to chow and water. The animal cages were grouped around devices within a one-meter radius, including a Wi-Fi modem or a centrally placed mobile jammer (MB06 Mobile Blocker) [13]. The jammer disrupted communication by emitting radiation at four frequencies with a shielding radius of up to 40 m [14]. We used a D-Link DIR-600 L Wi-Fi modem (D-Link Corporation, Taiwan) and measured EMF with an Aaronia Spectran HF-4060 device (Euscheid, Germany). Additional information can be found in Table 1. The 2.45 GHz frequency is widely used due to its compatibility, coverage, cost-effectiveness, and device efficiency [14]. The rats were exposed to the Wi-Fi and mobile jammer groups. In major group A, three groups of 30 male rats were used, and the Wi-Fi group experienced 2.45 GHz radiation. In contrast, the mobile jammer group of rats was exposed to the active jammer route for two hours daily, five days a week, over two weeks. Sham group rats were exposed to inactive devices.

Since we observed that only the jammer group presented significant results, we decided to divide the second major group (B) into three subgroups: female, control pregnant, and jammer-exposed pregnant subgroups in the next step. After parturition, we generated two additional offspring subgroups: jammer-exposed and non-exposed. In other words, the control group of pregnant fetuses had normal conditions without radiation exposure, contributing to the parturition of normal offspring. However, the jammer-exposed subgroup of pregnant fetuses experienced abnormal conditions due to radiation, contributing to the parturition of irradiated offspring. We synchronized the estrous cycles of all females before the study.

After radiation, animals were anesthetized by intraperitoneal injection of 80 mg/kg ketamine (Sigma Aldrich Co.), sacrificed, and blood was collected for laboratory analysis. Serum samples were stored at -20 °C. Thyroid tissues were fixed in 10% formalin, embedded in paraffin, stained with H&E, and evaluated histologically via computer-assisted light microscopy for detailed tissue analysis [15].

Statistical analysis

Statistical analyses were conducted using GraphPad Prism version 6 (GraphPad Software, La Jolla, CA, USA). The Shapiro-Wilk test confirmed normality of the data distribution ($p > 0.05$). Separate one-way analyses of variance (ANOVA) revealed significant differences in the means of T3 and T4 levels among the groups. Tukey's

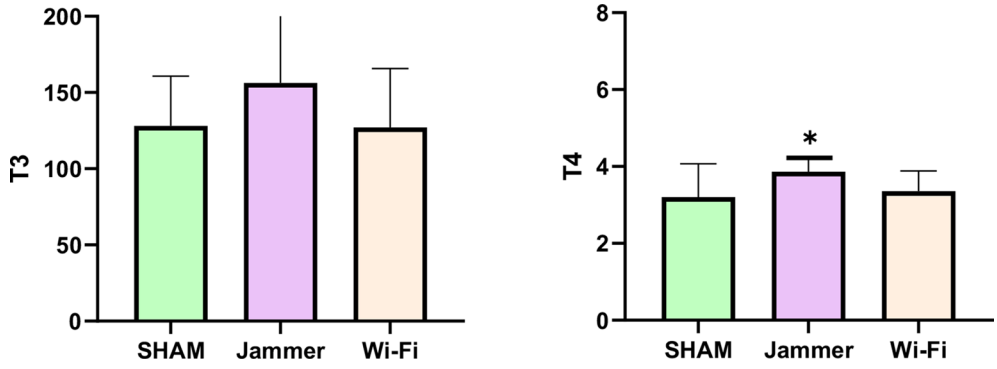

Fig. 1 Shows the average concentrations of the T3 and T4 hormones in the Sham, Jammer, and Wi-Fi groups (for T4, the jammer group showed a significant increase (p=0.037)) (Error bars: ±2 SD). * Demonstrated a significant difference

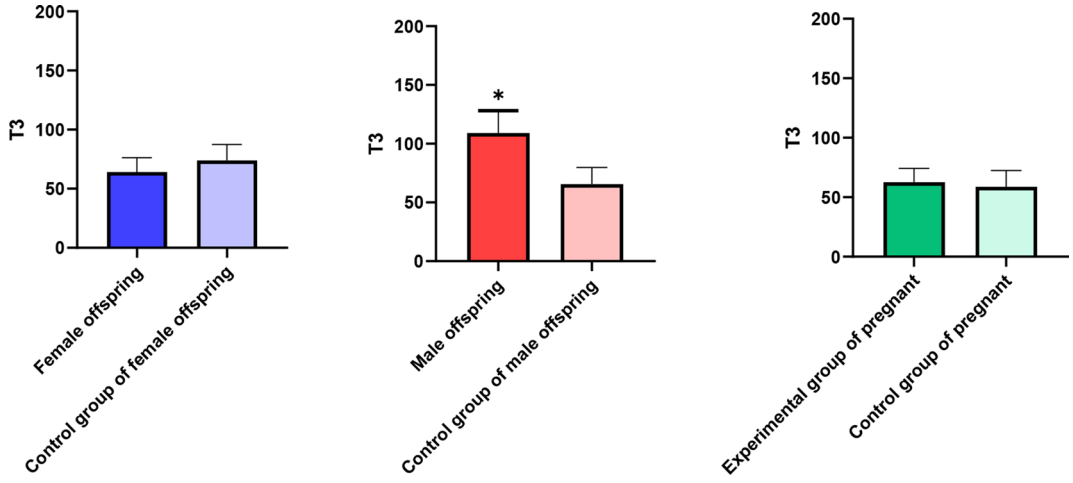

Fig. 2 Shows the mean blood T3 hormone concentrations for experimental female offspring compared with those of the control group, experimental male offspring compared with those of the control group, and the experimental pregnant group compared with those of the control pregnant group (male offspring significantly increased (p<0.001)) (Error bars: ±2 SD). * Demonstrated a significant difference

post hoc test was used to identify specific pairwise differences between groups. A p-value of less than 0.05 was considered statistically significant.

Results

Group A results

For the T3 hormone levels, the Sham group had a mean concentration of 120 ng/dL, the Wi-Fi group had a value of 130 ng/dL, and the Jammer group had the highest concentration of 200 ng/dL. T4 levels showed similar trends: the sham group at 3.0 μg/dL, the Wi-Fi group at 3.5 μg/dL; However, the Jammer group at 4.0 μg/dL showed a significant increase (p-value = 0.037) (Fig. 1).

Group B results

T3 levels

Compared with those in the control group (73.88 ng/dL), the levels in the female offspring in the experimental group were slightly lower (64.00 ng/dL). Male offspring significantly increased (109.00 ng/dL vs. 65.50 ng/dL in the control group) (p-value < 0.001). The pregnant group had comparable levels (62.56 ng/dL in the experimental group vs. 58.78 ng/dL in the control group) (Fig. 2).

T4 levels

In the female offspring in the experimental group, the mean T4 level was 4.56 μg/dL, whereas it was 2.74 μg/dL in the control group. Results for the male offspring in the experimental group were 3.73 μg/dL, whereas the male offspring in the control group were 2.59 μg/dL. In the pregnant group, we observed slightly lower levels at 2.60 μg/dL in the experimental group than at 2.77 μg/dL in the control group. The T4 hormone results revealed that the female and male offspring exposed to radiation were not significantly different from those in the male and female control groups (Fig. 3).

The T3 hormone level analysis revealed that only the irradiated male offspring group showed a significant difference from the other groups. On the other hand, the T4 hormone results showed that the female and male offspring exposed to radiation were not significantly different from those in the male and female control groups.

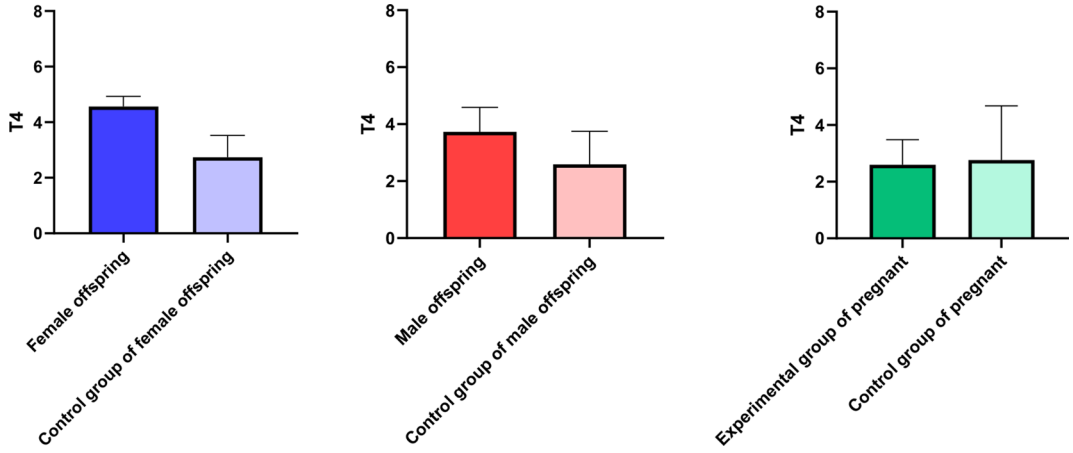

Fig. 3 Shows the mean blood T4 hormone concentrations for the experimental female offspring and their control groups, the experimental male offspring and their control groups, and the experimental pregnant and control pregnant groups (Error bars: ±2 SD)

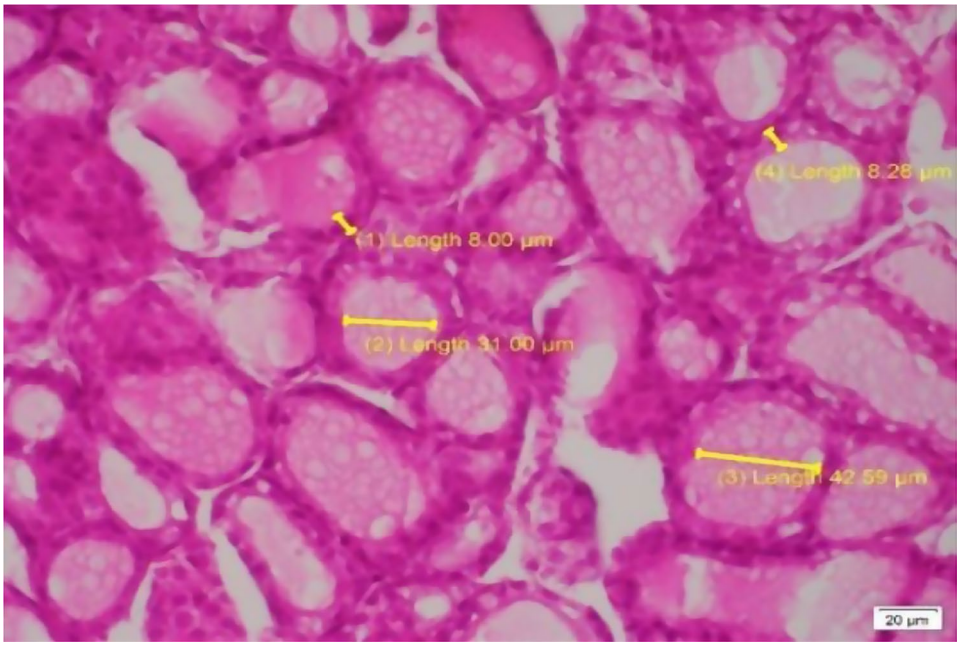

Image 1 The control male offspring group has medium-sized follicles with light-stained colloids in the central part of the thyroid tissue, and the size of the follicular cells is noted

Histopathology

A histological thyroid examination was performed on the thyroid colloid and epithelium in the follicles via computer-assisted microscopy. The magnification and setup were as follows: Microscope: Olympus BX-53, bright light upright configuration. Camera: Olympus DP27. We also added and evaluated the adult sham group. Images 1, 2, 3 and 4 show a volume difference in the colloid fluid between the peripheral and central regions and a noticeable alteration in the follicular cells, including their thickness and size. The experimental groups presented differences in follicular structure and colloid distribution. The follicles in the control male offspring group were medium-sized with lightly stained colloids. In the non-pregnant irradiated subgroup, numerous large follicles with loss of colloids were observed, whereas the adult male sham subgroup presented large follicles containing high-staining colloids. The periphery region of the irradiated pregnant group presented large colloid-filled follicles. These observations highlight the differences between the groups in follicular size, colloid staining, and follicular cell morphology.

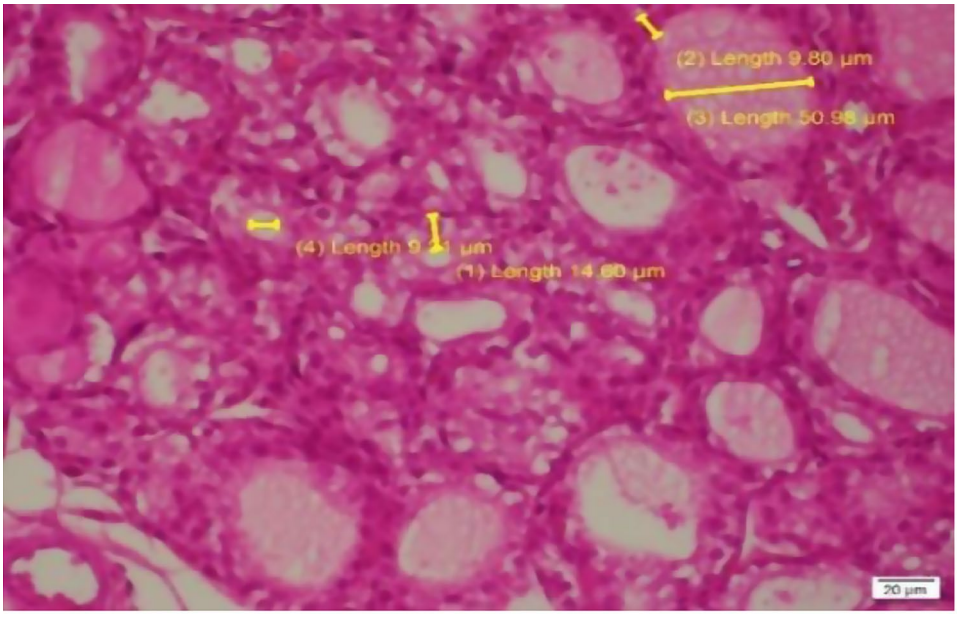

Image 2 Irradiation in the non-pregnant group results in the accumulation of light-stained colloids in large follicles and the absence of colloids in most follicles, along with changes in the length of follicular cells

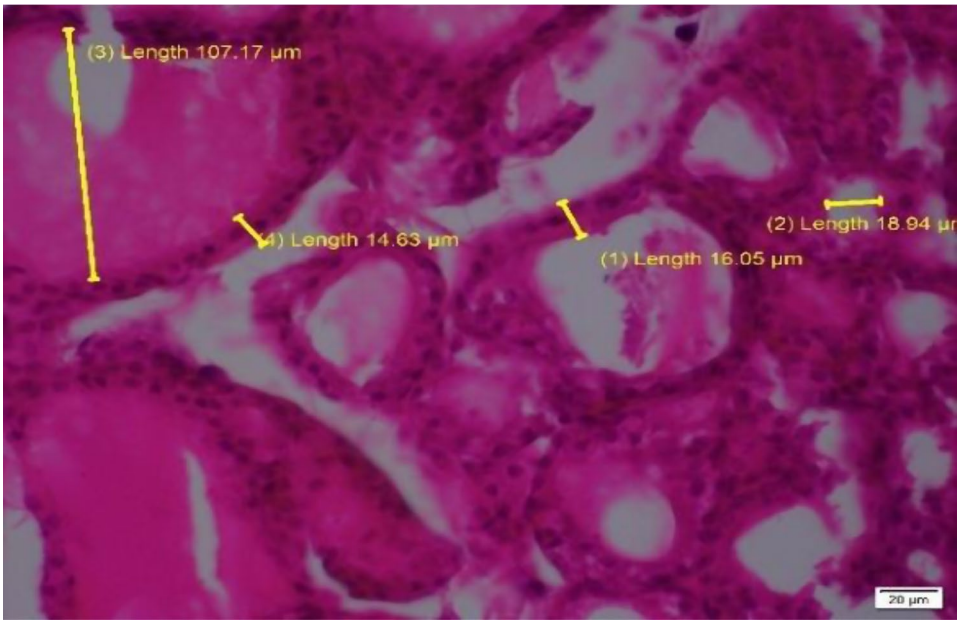

Image 3 The adult male sham group shows an accumulation of highly stained colloids in large follicles, while there is an absence of colloids in most of the follicles. Additionally, the length of the follicular cells is noted

Discussion

The thyroid gland is particularly susceptible to the harmful effects of non-ionizing radiation and is located in the anterior part of the neck. Several studies have linked non-ionizing radiation exposure to thyroid gland functional impairment and alterations in serum thyroid hormone levels, as well as insufficient thyroid activity and enhanced or impaired activity of the hypothalamic-pituitary-thyroid axis, supporting our findings. In addition, histopathological alterations in thyroid gland follicles have been reported in rats exposed to non-ionizing type radiation, which varies according to the intensity and exposure period of the EMF [16, 17]. It has been reported that long-term exposure to an EMF affects thyroid metabolism by increasing total oxidative stress and decreasing antioxidant status [18]. Wireless devices typically send and receive information via multiple antennas at once, which may lead to environmental changes and

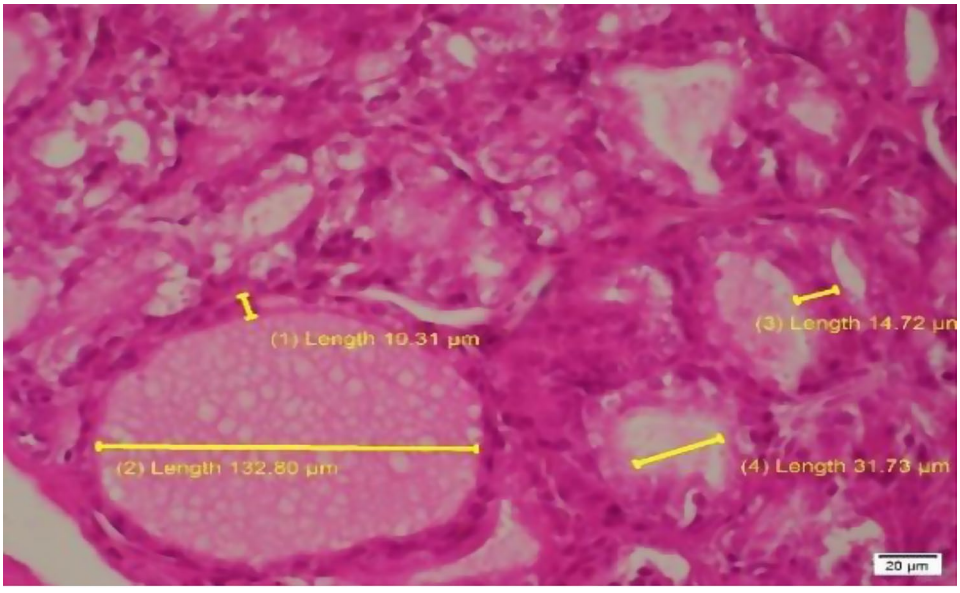

Image 4 The irradiated pregnant group shows large colloid follicles in the periphery and medium-sized follicles with light-stained colloids in the central part of the thyroid tissue, along with the length of the follicular cells

biological effects [19]. Studies suggest that children are more sensitive to the impact of this radiation than adults are, since their growth and development rates are higher [20]. Moreover, children's brain tissue, thinner skulls, and higher water content in their cerebral tissues allow EMFs to penetrate their brains more quickly [21, 22]. The same applies to other tissues, such as the thyroid gland, near radiation sources [19]. Findings from a 2021 cohort study of Chinese medical radiation workers indicated that thyroid hormone secretion might be disrupted in a low-dose radiation exposure environment [23]. The 2021 ORSAA database also includes 15 experimental studies, 10 observational studies, and four reviews, revealing thyroid abnormalities such as increased follicular epithelial tissue, reduced colloid volume, and altered follicular fluid, which aligns with our findings [24]. Another study revealed histopathological changes in thyroid gland follicles after rats were exposed to non-ionizing radiation, and results were directly related to the amount and duration of exposure to EMF radiation [17]. In our study, light microscopic examination revealed significant morphological changes in the follicular epithelium, including alterations in cell height, thickness, and colloid fluid volume across some groups, and Esmekaya et al. reported similar findings [25, 26]. Thyroid gland activity is correlated with the volume of colloid fluid. H&E staining revealed disrupted walls, degenerated colloids, and vacuolated cytoplasm. These findings were consistent with those reported by Mohamed and Elnegris [27]. Exposure to electromagnetic fields can alter thyroid gland function and structure by inducing ROS through non-thermal effects. Further research is needed on the effects of EMF on thyroid hormone transporters and the establishment of safety standards to protect future generations [26]. Additionally, as shown in Fig. 1, the T3 levels of adult male rats in the jammer and Wi-Fi groups were compared with those in the sham group and were not found to be significantly different. This is likely due to its shorter half-life compared to the T4 effect, which has a shorter action. While T3 has significantly greater biological activity than T4, it is produced in peripheral tissues through the deiodination of T4.

This study addresses the biological effects of non-ionizing radiation on oxidative stress. To achieve this, we evaluated the interaction between electromagnetic waves emitted by Wi-Fi and jammer devices in adult males and females (pregnant and non-pregnant) and their offspring rats. Considering that the histopathology of the thyroid is similar in humans and rodents, the rat was chosen for this assessment. Figure 1 shows that T4 was significantly greater in adult male rats in the jammer group than in those in the sham group. This finding suggests that the jamming router's capacity to interfere with Wi-Fi signals may have shielded the adult male thyroid gland from radiation. In contrast, compared with mothers exposed to jammer radiation, the analysis of serum thyroxin hormone levels in offspring rats from the mother rats showed significant increases in males of offspring rats.

Conclusion

Changes in serum thyroid hormone levels and histopathological alterations in the thyroid gland, including changes in the volume of follicular cells and follicular fluid, were observed in rats after exposure

to non-ionizing radiation. These changes are probably related to the amount and duration of exposure to electromagnetic field (EMF) radiation, which affects both adults and offspring. These findings underscore the importance of further research into the biological effects of non-ionizing radiation, particularly its potential impact on thyroid function.

Limitations

This study encountered several limitations, including the high costs of maintaining animal subjects, acquiring necessary equipment, and performing histological analyses. Additionally, restrictions on using mobile jammers regarding location, timing, and duration limit the variety of exposure conditions. The small sample size poses a challenge; while the minimal effect size can be statistically significant, statisticians typically recommend using at least seven animals per group in animal studies. Ethical animal rights guidelines also advocate using the smallest possible number of animals. These factors underline the necessity for broader experimental designs and longer-term studies in future research.

Acknowledgements
The authors appreciate the support of Shiraz University of Medical Sciences.

Author contributions
Z.S. contributed to manuscript writing and actively participated in the experimental stages. A.E. was involved in manuscript editing, experimental procedures, and article submission. A.T. provided expertise and contributed to the histopathological analyses. M.S. led the study's conception and design, oversaw data collection, analyzed and interpreted the results, and contributed to manuscript preparation.

Funding
The present study was financially supported by Shiraz University of Medical Sciences, School of Medicine, Ionizing and Non-ionizing Radiation Protection Research Center, Shiraz, Iran.

Data availability
The data supporting this study's findings are available upon request from the corresponding authors.

Declarations

Ethics approval and consent to participate
The Animal Research Ethics Committee at the Faculty of Medicine, Shiraz University of Medical Sciences, approved this project with the Ethics Code: IR.SUMS.REC.1393.6756.

Consent for publication
Not applicable.

Competing interests
The authors declare no competing interests.

Received: 30 December 2024 / Accepted: 14 May 2025
Published online: 24 May 2025

References

1. Yari S, Asadi AF, Jarrahi AM, Nourmohammadi M. Biological effects of electromagnetic waves with emphasis on radio and microwave: an environmental carcinogen. Asian Pac J Environ Cancer. 2019;2(1):35–41.
2. Mohamed MN, Saleh SI, Asaad Amin M, Khattab RT, Isaac MR, Ahmed Zakaria MM. Histological study on the effect of electromagnetic radiation emitted from 4G cell phones on the thyroid gland of the adult male albino rat. Egypt J Histol. 2023;46(3):1108–19.
3. Gherardini L, Ciuti G, Tognarelli S, Cinti C. Searching for the perfect Wave: the effect of radiofrequency electromagnetic fields on cells. Int J Mol Sci. 2014;15(4):5366–87.
4. Sies H, Jones DP. Reactive oxygen species (ROS) as pleiotropic physiological signalling agents. Nat Rev Mol Cell Biol. 2020;21(7):363–83.
5. Peepre K, Deshpandey U, Choudhary P. Role of antioxidants on thyroid hormones in Wister rats. Int J Sci Res. 2014;3(1):34–8.
6. Kochman J, Jakubczyk K, Bargiel P, Janda-Milczarek K. The influence of oxidative stress on thyroid diseases. Antioxidants. 2021;10(9):1442.
7. Corvilain B, Van Sande J, Laurent E, DUMONT JE. The H2O2-generating system modulates protein iodination and the activity of the Pentose phosphate pathway in dog thyroid. Endocrinology. 1991;128(2):779–85.
8. Uscebrka G, Zikic D, Matavulj M, Rajkovic V, Gledic D. Electromagnetic field effects on the morphometrical characteristics of rat adrenal glands. Electricity Magnetism Biology Med. 1999:485–8.
9. Pirayesh H, Zeng H. Jamming attacks and anti-jamming strategies in wireless networks: A comprehensive survey. IEEE Commun Surv Tutorials. 2022;24(2):767–809.
10. Capotă C, Popescu M, Bădulă E-M, Halunga S, Fratu O, Popescu M. Intelligent jammer on mobile network LTE technology: A study case in Bucharest. Appl Sci. 2023;13(22):12286.
11. Madara DS, Ataro E, Sitati S. Design and testing of a mobile-phone-jammer. Innovative Syst Des Eng. 2016;7(7):7–18.
12. Misa-Agustino MJ, Jorge-Mora T, Jorge-Barreiro FJ, Suarez-Quintanilla J, Moreno-Piquero E, Ares-Pena FJ, et al. Exposure to non-ionizing radiation provokes changes in rat thyroid morphology and expression of HSP-90. Experimental Biology Med. 2015;240(9):1123–35.
13. Shahi A, Shahnazar F, Nematolahi S, Dehghan A, Shojaeifard M. Does exposure to radiation emitted from mobile jammers influence the Spatial memory? Int J Radiation Res. 2021;19(4):993–1000.
14. Yazdanpanahi M, Namazi A, Shojaeifard MB, Nematolahi S, Pourahmad S. Evaluating the effect of jammer radiation on learning and memory in male rats. J Biomedical Phys Eng. 2023;13(1):29.
15. Sambucci M, Laudisi F, Nasta F, Pinto R, Lodato R, Altavista P, et al. Prenatal exposure to non-ionizing radiation: effects of WiFi signals on pregnancy outcome, peripheral B-cell compartment and antibody production. Radiat Res. 2010;174(6a):732–40.
16. Rai G, Kumar A, Mahobiya P. The effect of radiation on thyroid gland. Int J Biol Res. 2018;3:217–22.
17. Alkayyali T, Ochuba O, Srivastava K, Sandhu JK, Joseph C, Ruo SW et al. An exploration of the effects of radiofrequency radiation emitted by mobile phones and extremely low frequency radiation on thyroid hormones and thyroid gland histopathology. Cureus. 2021;13(8).
18. Kunt H, Şentürk İ, Gönül Y, Korkmaz M, Ahsen A, Hazman Ö et al. Effects of electromagnetic radiation exposure on bone mineral density, thyroid, and oxidative stress index in electrical workers. OncoTargets Therapy. 2016:745–54.
19. Davis D, Birnbaum L, Ben-Ishai P, Taylor H, Sears M, Butler T, et al. Wireless technologies, non-ionizing electromagnetic fields and children: identifying and reducing health risks. Curr Probl Pediatr Adolesc Health Care. 2023;53(2):101374.
20. Rice D, Barone S Jr. Critical periods of vulnerability for the developing nervous system: evidence from humans and animal models. Environ Health Perspect. 2000;108(suppl 3):511–33.
21. Gandhi OP. Yes the children are more exposed to radiofrequency energy from mobile telephones than adults. IEEE Access. 2015;3:985–8.
22. Morris RD, Morgan LL, Davis D. Children absorb higher doses of radio frequency electromagnetic radiation from mobile phones than adults. Ieee Access. 2015;3:2379–87.
23. Guo QS, Ping R, Huang WX, Qiu JC. Occupational radiation exposure and changes in thyroid hormones in a cohort of Chinese medical radiation workers. Biomed Environ Sci. 2021;34(4):282–9.

24. Zufry H, Rudijanto A, Soeatmadji DW, Sakti SP, Munadi K, Sujuti H, et al. Do electromagnetic fields significantly affect thyroid cells and their functions?–A systematic review. F1000Research. 2024;13:12.
25. Ibrahim NNAE-H, Estfanous RS, Abo-Alala AM, Elkattan AK, Amer RM. Effect of electromagnetic radiation of Wi-Fi router on thyroid gland and the possible protective role of combined vitamin C and zinc administration in adult male albino rats. J Microscopy Ultrastructure. 2024;12(2):51–61.
26. Eşmekaya MA, Seyhan N, Ömeroğlu S. Pulse modulated 900 mhz radiation induces hypothyroidism and apoptosis in thyroid cells: a light, electron microscopy and immunohistochemical study. Int J Radiat Biol. 2010;86(12):1106–16.
27. Mohamed DA, Elnegris HM. Histological study of thyroid gland after experimental exposure to low frequency electromagnetic fields in adult male albino rat and possible protective role of vitamin E. J Cytol Histol. 2015;6(6):1.

Publisher's note

Springer Nature remains neutral with regard to jurisdictional claims in published maps and institutional affiliations.